

Osteotomy at Low-Speed Drilling without Irrigation *Versus* High-Speed Drilling with Irrigation: an Experimental Study



Osteotomia a Baixa Rotação sem Irrigação *Versus* Alta Rotação com Irrigação: Estudo Experimental

João GASPAR¹, Gonçalo BORRECHO², Pedro OLIVEIRA¹, Francisco SALVADO³, José MARTINS dos SANTOS¹
Acta Med Port 2013 May-Jun;26(3):231-236

ABSTRACT

Introduction: Excessively traumatic surgery can adversely affect the maturation of bone tissue and consequently diminish the predictability of osseointegration so the mechanical and thermal damage should be minimized during surgical procedure. The purpose of this study is to evaluate immediate histological alterations in rabbit tibias, produced by low speed drilling (50 rpm) without irrigation and conventional drilling (800 rpm) under profuse irrigation.

Material and Methods: Thirty-six implant osteotomies were created in the tibias of 6 White female rabbits. Drilling began with a 1.5 mm round bur, followed by 2.0 mm, 2.5 mm and 3.5 mm helical drills. The posterior tibial cortex was evaluated as the positive control, and it was preserved during the surgical procedure. The receptor beds were collected for histological analysis.

Results: All defects showed regular edges. Hematoxylin eosin (HE) sections showed that both techniques preserved the bone structure and the presence of living cells. No histological differences between the two surgical drilling techniques were found.

Conclusions: Based on our results, we can conclude that the effects of implant site preparation on bone by low speed drilling (50 rpm) without irrigation and conventional drilling (800 rpm) under abundant irrigation are similar. Both surgical drilling techniques preserve bone-cell viability and the clinician can decide which drilling technique to use, based on other criteria.

Keywords: Osteotomy; Osseointegration; Rabbits; Therapeutic Irrigation; Tibia; Wound Healing.

RESUMO

Introdução: A cirurgia traumática pode afetar a maturação do tecido ósseo e, diminuir a previsibilidade de osteointegração, pelo que a lesão mecânica e térmica deve ser minimizada. O objectivo deste estudo foi avaliar as alterações histológicas imediatas provocadas pela osteotomia a 50 rpm sem irrigação e a 800 rpm com irrigação, no osso do coelho.

Material e Métodos: Foram efectuadas 36 perfurações (18 com cada técnica) nas tibias de seis coelhos adultos. A sequência de brocas utilizada foi: uma broca esférica com 1,5 mm de diâmetro, uma broca piloto com 2,0 mm de diâmetro, e uma broca com 3,5 mm de diâmetro. A cortical posterior das tibias foi preservada, constituindo o osso de controlo. Procedeu-se à recolha das tibias com os defeitos a analisar, para observação com microscópio óptico e análise qualitativa.

Resultados: Os defeitos ósseos apresentaram bordos regulares. Observou-se tecido ósseo viável, vascularizado e com presença de osteócitos junto aos defeitos. A estrutura haversiana e lamelar do tecido encontrou-se mantida, bem como a rede vascular. A matriz extracelular não apresentou alterações. Os resultados indicam não haver diferenças histológicas entre as osteotomias a 800 rpm com irrigação e a 50 rpm sem irrigação.

Conclusão: O nosso estudo sugere que as alterações no tecido ósseo provocadas pela osteotomia a 50 rpm sem irrigação e a 800 rpm com irrigação são semelhantes, e que ambas as técnicas mantêm o tecido ósseo viável para a colocação de implantes e respectiva osteointegração, cabendo ao clínico a escolha, em função de outras variáveis.

Palavras-chave: Coelhos; Irrigação Terapêutica; Osteointegração; Osteotomia; Tibia.

INTRODUCTION

Oral rehabilitation with endosseous implants represents a safe and viable treatment option with high success rates; however, it depends on osseointegration.¹⁻³ There are many parameters that must be taken into account during implant site preparation which should be as atraumatic as possible, for osseointegration to occur.^{1,4-7} Excessively traumatic surgery can adversely affect the maturation of bone tissue at the bone/implant interface and consequently diminish the predictability of osseointegration⁸ so the mechanical and thermal damage should be minimized during surgical procedure.^{7,9} The viability of the bone tissue depends on several factors: rotational speed^{6,10-12}; irrigation^{7,13-15}; type of osteotomy (continuous or intermittent)⁸; temperature¹⁶; pressure applied during drilling¹⁷; shape, size and cutting edge

of the drills¹⁸; duration of bone heating and density of the bone.^{7,8,19}

Implantology and its surgical techniques are in constant evolution. Most implant systems recommend similar drilling protocols (from 800 to 1500 rpm), using profuse irrigation in order to avoid overheating generated by the drill. Recently there has been suggested a new concept of low speed drilling (50 rpm) without irrigation as an alternative to the conventional procedure with irrigation.²⁰ This technique can provide some advantages including collecting autologous bone²¹ without the need for additional surgery.²² It is possible to recover directly the bone cut by the drills without contamination by saliva, which can be used for an autograft.²⁰ Low-speed drilling can also give the operator more

1. Centro de Investigação Interdisciplinar Egas Moniz (CiIEM). Instituto Superior de Ciências da Saúde Egas Moniz. Monte de Caparica. Portugal.

2. Serviço de Anatomia Patológica. Hospital de Santa Maria. Lisboa. Portugal.

3. Serviço de Anatomia Patológica. Faculdade de Medicina da Universidade de Lisboa. Portugal.

Recebido: 30 de Novembro de 2012 - Aceite: 03 de Março de 2013 | Copyright © Ordem dos Médicos 2013

precise information of the path of the drill so that the operator can correct it if necessary. Thus, by drilling at low speed it is possible to better control the osteotomy.²¹

The purpose of this study is to evaluate the immediate histological alterations, in rabbit tibias, produced by low speed drilling (50 rpm) without irrigation and conventional drilling (800 rpm) under abundant irrigation.

MATERIAL AND METHODS

Sample

This study used 6 White adults female rabbits (*Oryctolagus cuniculus*, New Zealand White) with body weights of 4.0 kg ± 0.5 kg. The animals were acquired in a local rabbit breeder.

The animals were placed in individual cages appropriate for the species in the ward for animals of Instituto Superior de Ciências da Saúde Egas Moniz. They were fed a standard ration and had free access to water originating from the municipal supply. The animals were treated according to the European Union Directive on Animal Welfare for Scientific and Experimental (86/609/CE) and to the transposition into Portuguese legislation to the same effect (Decree-Law 197/96).

Material

IDI implant drill system (IDI®, France) was used in this study. The drills are made of stainless steel (Sandvik 4C27A, ASTM 420F), highly resistant to wear, with great cutting capacity.

An electric motor (W.H. Implantmed®) connected to a 20:1 reduction contra-angle was used to perform the osteotomies.

Surgical procedure

The animals were anesthetized by intramuscular administration of a combination of 0.12 mg/kg of medetomidine hydrochloride and 20 mg/kg of ketamine. The heart and respiratory rate were monitored during the entire anesthetic period.

After skin exposure, an incision in the medial portion of the right and left tibias of each rabbit was made, followed by detachment of the periosteum to perform the osteotomies.

Six osteotomies were made for each animal: three at 800 rpm with saline irrigation (right tibia) and three at 50 rpm without irrigation (left tibia) (Figs 1 and 2). It was maintained a distance of about 6 mm between the defects.

The drill sequence used was: 1.5 mm round bur, followed by 2.0 mm, 2.5 mm and 3.5 mm helical drills.

The pressure exerted on bone during drilling was not measured; however, all the osteotomies were performed by the same operator with low pressure and intermittently so that there is a standardization throughout the procedure. The posterior tibial cortex was evaluated as the positive control and it was preserved during the surgical procedure. After surgical procedure, the animals were sacrificed with a lethal dose of thiopental sodium intraperitoneally. The tibias were collected and the defects were fixed in 10% formaldehyde solution.

The samples were then processed, sectioned transversely and stained with hematoxylin and eosin for light microscopy observation, photography and qualitative analysis. There were made two histological sections from each one of the 36 defects, a total of 72 sections.

RESULTS

Histological analysis of the 36 osteotomies was made by observation with an optical microscope. All defects showed regular edges. As intended, the posterior tibial cortex was preserved in all parts.

All the histological sections showed more exact cutting line in the compact bone than in the cancellous bone.

For the cancellous bone, there was observed greater bone destruction in defects produced at 800 rpm with irrigation, with the presence of splinters, bleeding and disruption of bone marrow (Fig. 3).

On the other hand, with drilling at 50 rpm without irrigation, the cancellous bone was more preserved and 'cleaner' (Fig. 3).

For the cortical bone, no differences were found between the osteotomized bone and the posterior cortex (control), with both drilling techniques (Fig. 4).

Microscopic examination showed that both techniques preserved the bone structure. The lamellar and haversian systems were maintained as well as the vascular network.

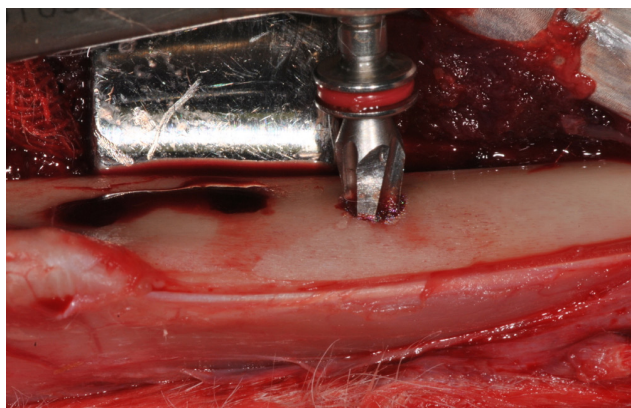


Figure 1 – Osteotomy at 50 rpm without irrigation.



Figure 2 – Bone collected during low-speed drilling (50 rpm) without irrigation.

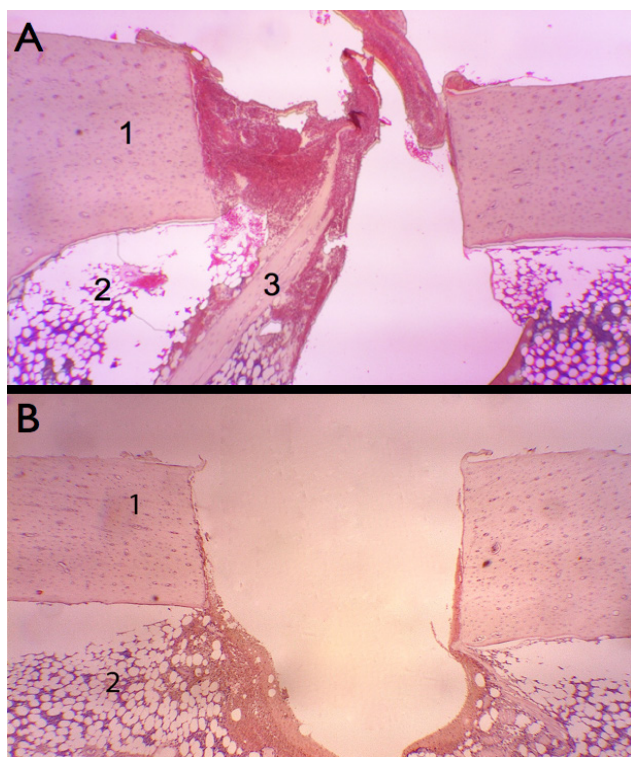


Figure 3 – A - Osteotomy at 800 rpm with irrigation (H-E, 40x) It is observed disruption of bone marrow (2) and a splinter (3). 1: cortical bone; 2: cancellous bone; 3: splinter
B - Osteotomy at 50 rpm without irrigation (H-E, 40x) It is observed preservation of cancellous bone. 1: cortical bone, 2: cancellous bone.

The extracellular matrix did not show changes (Fig. 5). Near the defects the osteocytes showed no morphological alterations.

In summary, the current results indicate that no histological differences between the two surgical drilling techniques were found (Fig. 6).

DISCUSSION

In implantology, traumatic surgery may lead to the formation of connective tissue around the implant, which will hamper its anchorage to the bone.²³ Heat is always generated during implant drilling.⁶ A significant increase in temperature can result in considerable damage in the bone tissue. Apart from thermal damage, osteotomy may also cause mechanical damage to the surrounding bone.²¹ Thus, to preserve the viability of the bone⁸ and to avoid excessive heat generation during implant site preparation, it is essential to practice a proper surgical technique.⁶

Our study, as well as several similar experimental studies,^{1,8,11,23,24} was conducted in rabbit tibias. The maxilla and the mandible are bones of intramembranous origin, unlike the tibia which is of endochondral origin. However, in the adult, the structure of the bone tissue formed by the two ossification mechanisms is indistinguishable²⁶ so the conclusions were not affected.

Clinically, there is no way to accurately measure the pressure that is applied to the handpiece during osteoto-

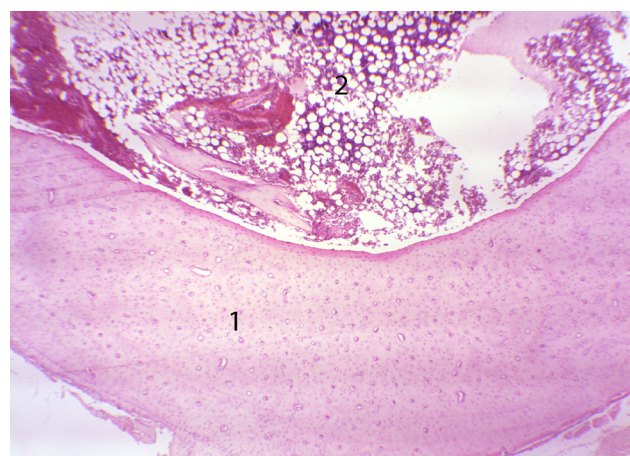


Figure 4 – Posterior cortical preserved (control) (H-E, 40x) 1: cortical bone, 2: cancellous bone.

my. Therefore, by keeping the rotational speed constant it is likely for the operator to apply more pressure during the drilling of cortical bone, thus producing more frictional heat and a rise in temperature of the bone tissue.¹ In this study, osteotomies were performed in dense cortical bone (type I),⁸ which apparently viable in the immediate in both drilling techniques. Thus, in less dense bone, it is expected that results are at least similar, because of lower production of frictional heat.

In the literature, there seems to be no consensus on the most recommended method of irrigation. Some authors^{14,26} reported advantages of using internal irrigation; on the other hand, according to Benington et al,⁷ it seems not to exist significant differences between the two methods. In this study, external irrigation was used (in the case of the osteotomies at 800 rpm). The osteotomies were performed at low pressure and intermittently, to avoid interference between the output of bone fragments and the intake of the cooling liquid; thus the irrigation could reach the implant bed and the tip of the drill, in order to reduce the friction caused by this. Continuous drillings in deep osteotomies can produce potentially damaging temperatures to the bone tissue.²⁷ According to Sharawy et al,⁶ it may be beneficial a waiting period between each drill sequence in an osteotomy so as to cool the bone thus avoiding an excessive heat production. Implant and surgical drilling technique interplay that provides low levels of compressive stress immediately after placement, high degrees of implant primary stability and low degrees of micromotion have been regarded as potential benefits in the quest for atemporal implant stability during the early stages of osseointegration.²⁸ Therefore, the differences we have found in the cancellous bone between the two drilling techniques may not be relevant since implant primary stability is essentially given by the anchorage in the cortical bone.

Drill wear caused by repeated use may result in increased heat production¹⁸ and further damage to the bone tissue, thus affecting the process of osseointegration of implants.⁸ In our study, we used two new drill sequences: each sequence completed 18 osteotomies.

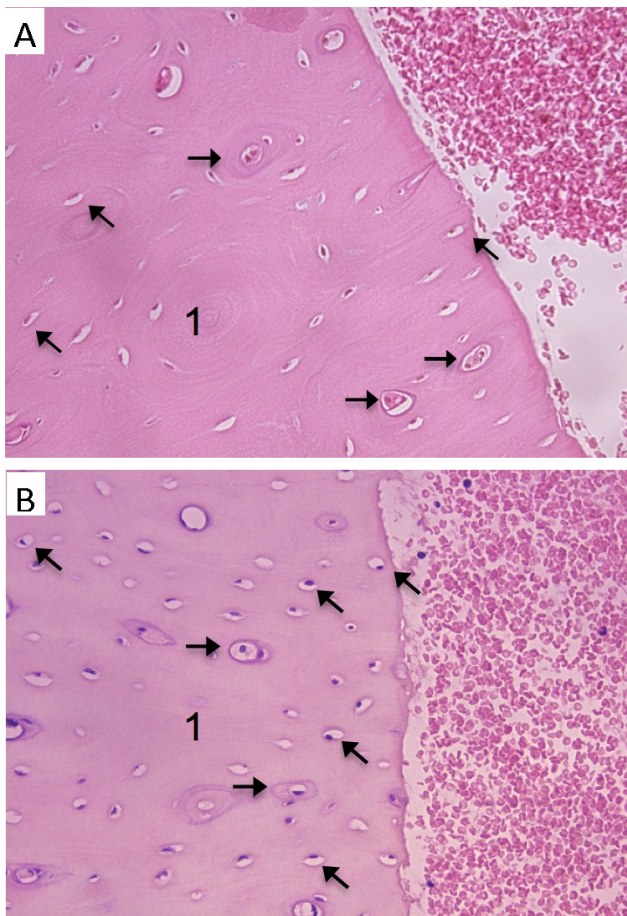


Figure 5 – A - Osteotomy at 800 rpm with irrigation (H-E, 400x) Cortical bone near the surgical defect. It is observed normal bone tissue.

1: cortical bone; oblique arrows: lacunae filled with osteocytes; horizontal arrows: Haversian canals

B - Osteotomy at 50 rpm without irrigation (H-E, 400x)

Cortical bone near the surgical defect. It is observed normal bone tissue.

1: cortical bone; oblique arrows: lacunae filled with osteocytes; horizontal arrows: Haversian canals

The aim of this study was to evaluate histologic alterations (in the immediate period) caused by two types of osteotomy: 800 rpm with irrigation, commonly used by many clinicians and in previous studies^{29,30} and 50 rpm without irrigation, a more recent alternative to conventional procedures, which can bring some advantages.^{20,21} Giro et al³¹ evaluated the effect of the surgical technique on implant integration, by performing osteotomies at 50 rpm without irrigation and 900 rpm with irrigation. The authors concluded that both techniques showed similar results and did not affect the integration of implants.³¹

Kim et al²¹ measured the temperature change during implant site preparation by drilling at 50 rpm without irrigation with three different drill systems, and in neither case was excessive heat production. Irrigation can have a negative effect by washing away and dissolving osteoinductive signaling proteins and other biomolecules present in bone extracellular matrix, which have an important role in bone

remodeling.²⁰

One of the advantages of the concept of low-speed drilling without irrigation is the easy control of the drilling path; however, it has the disadvantage of being a more time consuming procedure. During conventional high-speed drilling, there may be an unintentional deviation of the drilling path. Low-speed drilling can inform the operator more precisely that the path has changed so that the operator can correct it if necessary.²¹ Furthermore, the potential risk of damaging the inferior alveolar nerve or invading vital structures such as the maxillary sinus is minimized with this technique.³²

The recovery of autologous bone through suction filters (in the conventional drilling procedure with irrigation) is more difficult; in addition, the presence of microorganisms is typically quite high, due to the presence of saliva,²¹ with the risk of complications associated with infection of collected bone particles. Therefore, decontamination methods (with chlorhexidine or clindamycin) of collected bone particles through suction filters should be considered to reduce the risk of graft failure due to bacterial contamination.³³ Low-speed drilling without irrigation is particularly recommended when an autograft is indicated since it allows to collect the bone directly from the drill, reducing contamination by saliva. The bone particles collected by this method are larger and viable, with osteocytes and bone architecture maintained.²⁰

This study only evaluated histologic alterations in bone tissue in the immediate period: It was observed bone tissue with regular edges, maintaining the characteristic lamellar structure with apparently normal osteocytes in both techniques. In our observations we haven't found alterations in the architecture of bone tissue that could determine severe anatomic alterations of the involved site. It was not possible to determine if there was bone necrosis in either case since the period of time between the surgery and the histological evaluation was too short.

It would be interesting to proceed with the study of bone tissue changes with an evaluation in a late period (to evaluate whether the changes would also be superposable), or with implant placement and evaluation of integration thereof.

CONCLUSION

Based on our results, we can conclude that the effects of implant site preparation on bone by low speed drilling (50 rpm) without irrigation and conventional drilling (800 rpm) under profuse irrigation are similar. Both surgical drilling techniques preserve bone-cell viability and the clinician can decide which drilling technique to use, based on other criteria.

ACKNOWLEDGMENTS

The authors wish to thank Odete Guimarães and Eduarda Silva their careful observation as well as their anatomical and pathological descriptions.

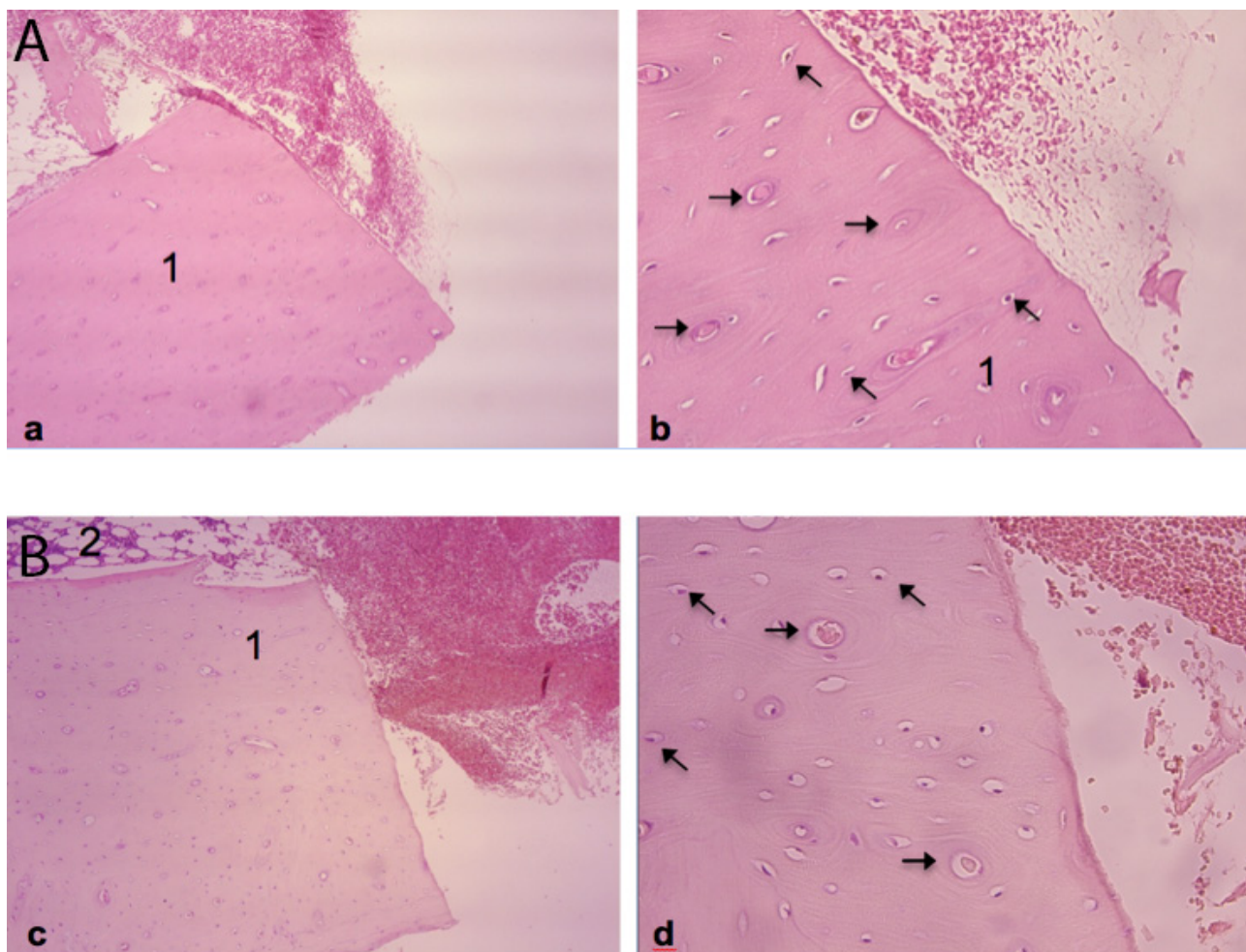


Figure 6 – A - Osteotomy at 800 rpm with irrigation (H-E, a: 100x; b: 400x)

The edges of the defect are regular, with viable bone tissue. It is observed gaps filled by osteocytes (oblique arrows) and lamellar and haversian systems maintained (horizontal arrows).

1: cortical bone

B - Osteotomy at 50 rpm without irrigation (H-E, c: 100x; d: 400x)

The edges of the defect are regular, with viable bone tissue. It is observed gaps filled by osteocytes (oblique arrows) and lamellar and haversian systems maintained (horizontal arrows).

1: cortical bone;

2: preserved cancellous bone.

CONFLICT OF INTERESTS

None stated.

FUNDING SOURCES

None stated.

REFERENCES

1. Queiroz TP, Souza FA, Okamoto R, Margonar R, Pereira-Filho VA, Garcia Júnior IR, et al. Evaluation of immediate bone-cell viability and of drill wear after implant osteotomies: immunohistochemistry and scanning electron microscopy analysis. *J Oral Maxillofac Surg.* 2008;66:1233-40.
2. Coelho PG, Suzuki M, Guimaraes MV, Marin C, Granato R, Gil JN, et al. Early bone healing around different implant bulk designs and surgical techniques: A study in dogs. *Clin Implant Dent Relat Res.* 2010;12:202-8.
3. Warreth A, Polyzois I, Lee CT, Claffey N. Generation of microdamage around endosseous implants. *Clin Oral Implants Res.* 2009;20:1300.
4. Brånemark PI, Hansson BO, Adell R, Breine U, Lindström J, Hallén O, et al. Osseointegrated implants in the treatment of the edentulous jaw. Experience from a 10-year period. *Scand J Plast Reconstr Surg Suppl.* 1977;16:1-132.
5. Albrektsson T, Brånemark PI, Hansson HA, Lindström J. Osseointegrated titanium implants. Requirements for ensuring a long-lasting, direct bone-to-implant anchorage in man. *Acta Orthop Scand.* 1981;52:155-70.
6. Sharawy M, Misch CE, Weller N, Tehemar S. Heat generation during implant drilling: the significance of motor speed. *J Oral Maxillofac Surg.* 2002;60:1160-9.
7. Benington IC, Biagioni PA, Briggs J, Sheridan S, Lamey PJ. Thermal changes observed at implant sites during internal and external irrigation. *Clin Oral Implants Res.* 2002;13:293-7.
8. Carvalho AC, Queiroz TP, Okamoto R, Margonar R, Garcia IR Jr, Magro Filho O. Evaluation of bone heating, immediate bone cell viability, and wear of high-resistance drills after the creation of implant osteotomies in rabbit tibias. *Int J Oral Maxillofac Implants.* 2011;26:1193-201.
9. Lee J, Rabin Y, Ozdoganlar OB. A new thermal model for bone drilling with applications to orthopaedic surgery. *Med Eng Phys.* 2011;33:1234-44.
10. Brisman DL. The effect of speed, pressure, and time on bone tempera-

- ture during the drilling of implant sites. *Int J Oral Maxillofac Implants.* 1996;11:35-7.
11. Iyer S, Weiss C, Mehta A. Effects of drill speed on heat production and the rate and quality of bone formation in dental implant osteotomies. Part I: Relationship between drill speed and heat production. *Int J Prosthodont.* 1997;10:411-4.
 12. Isler SC, Cansiz E, Tanyel C, Soluk M, Selvi F, Cebi Z. The effect of irrigation temperature on bone healing. *Int J Med Sci.* 2011;8:704-8.
 13. Eriksson AR, Albrektsson T, Albrektsson B. Heat caused by drilling cortical bone: Temperature measured in vivo in patients and animals. *Acta Orthop Scand.* 1984;55:629-31.
 14. Lavelle C, Wedgwood D. Effect of internal irrigation on frictional heat generated from bone drilling. *J Oral Surg.* 1980;38:499-503.
 15. Yacker MJ, Klein M. The effect of irrigation on osteotomy depth and bur diameter. *Int J Oral Maxillofac Implants.* 1996;11:634-8.
 16. Eriksson RA, Adell R. Temperatures during drilling for the placement of implants using the osseointegration technique. *J Oral Maxillofac Surg.* 1986;44:4-7.
 17. Matthews LS, Hirsch C. Temperatures measured in human cortical bone when drilling. *J Bone Joint Surg Am.* 1972;54:297-308.
 18. Chacon GE, Bower DL, Larsen PE, McGlumphy EA, Beck FM. Heat production by 3 implant drill systems after repeated drilling and sterilization. *J Oral Maxillofac Surg.* 2006;64:265-9.
 19. Watcher R, Stoll P. Increase of temperature during osteotomy. In vitro and in vivo investigations. *Int J Oral Maxillofac Surg.* 1991;20:245-49.
 20. Anitua E, Carda C, Andia I. A novel drilling procedure and subsequent bone autograft preparation: a technical note. *Int J Oral Maxillofac Implants.* 2007;22:138-45.
 21. Kim SJ, Yoo J, Kim YS, Shin SW. Temperature change in pig rib bone during implant site preparation by low-speed drilling. *J Appl Oral Sci.* 2010;18:522-7.
 22. Park SY, Shin SY, Yang SM, Kye SB. Effect of implant drill design on the particle size of the bone collected during osteotomy. *Int J Oral Maxillofac Surg.* 2010;39:1007-11.
 23. Eriksson AR, Albrektsson T. Temperature threshold levels for heat-induced bone tissue injury: a vital-microscopic study in the rabbit. *J Prosthet Dent.* 1983;50:101-7.
 24. Stadlinger B, Pourmand P, Locher MC, Schulz MC. Systematic review of animal models for the study of implant integration, assessing the influence of material, surface and design. *J Clin Periodontol.* 2012;39(Suppl. 12):28-36.
 25. Leite PH. Avaliação microscópica dos fragmentos ósseos obtidos por diferentes métodos de osteotomia e de irrigação em aloenxertos irradiados e congelados de coelho. Dissertação de Mestrado em Medicina Dentária, Universidade Federal do Rio Grande do Norte. Rio Grande do Norte: UFRGN; 2009.
 26. Harder S, Egert C, Wenz HJ, Jochens A, Kern M. Influence of the drill material and method of cooling on the development of intrabony temperature during preparation of the site of an implant. *Br J Oral Maxillofac Surg.* 2013;51:74-8.
 27. Ercoli C, Funkenbusch PD, Lee HJ, Moss ME, Graser GN. The influence of drill wear on cutting efficiency and heat production during osteotomy preparation for dental implants: a study of drill durability. *Int J Oral Maxillofac Implants.* 2004;19:335-49.
 28. Campos FE, Gomes JB, Marin C, Teixeira HS, Suzuki M, Witek L, et al. Effect of drilling dimension on implant placement torque and early osseointegration stages: an experimental study in dogs. *J Oral Maxillofac Surg.* 2012;70:e43-50.
 29. Coelho PG, Granato R, Marin C, Bonfante EA, Janal MN, Suzuki M. Biomechanical and bone histomorphologic evaluation of four surfaces on plateau root form implants: an experimental study in dogs. *Oral Surg Oral Med Oral Pathol Oral Radiol Endod.* 2010;109:e39-45.
 30. Allsobrook OF, Leichter J, Holborrow D, Swain M. Descriptive study of the longevity of dental implant surgery drills. *Clin Implant Dent Relat Res.* 2011;13:244-54.
 31. Giro G, Marin C, Granato R, Bonfante EA, Suzuki M, Janal MN, et al. Effect of drilling technique on the early integration of plateau root form endosteal implants: an experimental study in dogs. *J Oral Maxillofac Surg.* 2011;69:2158-63.
 32. Anitua E. New process for drilling, placing implants and obtaining autologous bone. *Implant Dialogue.* 2004;1:2-11.
 33. Tezulas E, Dilek OC. Decontamination of autogenous bone grafts collected from dental implant sites via osteotomy: a review. *Oral Surg Oral Med Oral Pathol Oral Radiol Endod.* 2008;106:679-84.