

Littre Hernia Associated with Cryptorchidism: A Rare Surgical Finding

Hérnia de Littré e Criptorquidismo: Uma Associação Cirúrgica Rara

Keywords: Cryptorchidism; Hernia; Meckel Diverticulum
Palavras-chave: Criptorquidismo; Divertículo de Meckel; Hérnia

A Littre hernia (LH) is an extremely rare hernia, with approximately 100 reported cases.¹ It is characterized by the presence of a Meckel's diverticulum (MD) within the hernia sac.¹

Cryptorchidism refers to an undescended testis that is not manually reducible into the scrotum.²

A 62-year-old male presented with a two-day history of severe abdominal pain in the lower quadrants. Bowel movements and flatus were present. The medical history included neuropsychomotor developmental delay and no prior surgeries. Physical examination revealed a painful, irreducible right inguinal bulge, with firm consistency, absent cough impulse, and overlying erythema. Ultrasonography confirmed a right inguinal hernia with strangulated bowel and an undescended testis in the inguinal canal.

Emergency surgery was performed. The hernia sac opening revealed a strangulated MD on the antimesenteric border of the ileal loop (Fig. 1). Segmental ileal resection, including the broad-base diverticulum, was performed, followed by side-to-side mechanical anastomosis. The atrophic undescended right testis was identified, and orchidectomy was performed, followed by Lichtenstein hernioplasty, an open tension-free technique that reinforces the posterior wall of the inguinal canal with a prosthetic mesh. In this case, a lightweight polypropylene mesh was used. The operative time was 100 minutes. The histopathological examination confirmed a MD. The right testicle was atrophic, with obliteration of the seminiferous tubule lumen, and there was a scarce number of Leydig cells, without malignancy. Re-evaluation at one month showed no hernia recurrence, and, at six months, the patient was asymptomatic.

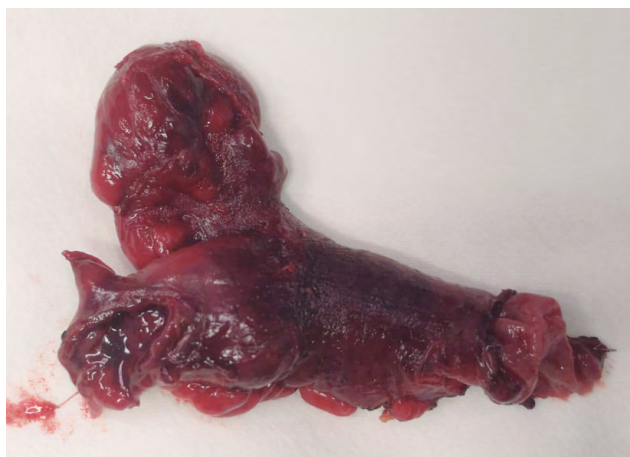

Figure 1 – Resected ileal segment with the broad-base Meckel diverticulum

Littre hernia may present as an incarcerated or strangulated hernia without symptoms of bowel obstruction, as presented here. If the initial compromise involves only the MD, the small bowel passage will be unaffected, and symptoms of obstruction may be absent.

Cryptorchidism in adults is rare, with an incidence of 0.23% - 1%.³ The association between cryptorchidism and inguinal hernia is well-known. In patients with undescended testes in the inguinal canal, the *processus vaginalis*, a peritoneal outpouching that accompanies the testis during its descent and normally obliterates after birth, may remain patent, with a subsequent risk of indirect inguinal hernia. To our knowledge, only two pediatric and one adult case of LH associated with cryptorchidism have been reported.^{4,5} This coexistence may be underreported, as both conditions are often diagnosed incidentally during surgery and associated findings are not always described in operative reports. It could be argued that the presence of a MD inside the hernia sac is an incidental finding. Nonetheless, if cryptorchidism leads to a patent *processus vaginalis* that can accommodate the bowel when a broad-base diverticulum enters the hernia sac, the probability of incarceration is high. In contrast to our case, Gamboa Miño *et al* opted for the mobilization and fixation of the testis in the scrotum, without resection, in their adult case.⁴ The risk of cancer, age of the patient, atrophic testis, and the need for a clear exposure to achieve tension-free hernia repair supported our decision to perform an orchidectomy.

Concomitant LH and cryptorchidism present diagnostic and therapeutic challenges. Management should be individualized according to clinical presentation and intraoperative findings.

PREVIOUS AWARDS AND PRESENTATIONS

This case was previously presented as an e-poster at the "XLIV Congresso Nacional de Cirurgia", organized by the Portuguese Surgical Society, March 14th and 15th, 2024, Cascais, Portugal.

ACKNOWLEDGMENTS

The authors have declared that no AI tools were used during the preparation of this work.

AUTHOR CONTRIBUTIONS

RFS: Study design; data collection and interpretation, writing of the manuscript.

NSG: Data collection and interpretation, writing and critical review of the manuscript.

CB, CV, JCP: Data collection and interpretation, critical review of the manuscript.

PROTECTION OF HUMANS AND ANIMALS

The authors declare that the procedures were followed according to the regulations established by the Clinical Research and Ethics Committee and to the Helsinki Declaration of the World Medical Association updated in October 2024.

DATA CONFIDENTIALITY

The authors declare having followed the protocols in use at their working center regarding patients' data publication.

REFERENCES

1. Răcăreanu M, Preda SD, Preda A, Strâmbu VD, Radu PA, Bratloveanu TC, et al. Management of Littre hernia-case report and systematic review of case reports. *J Clin Med*. 2023;12:3743.
2. Gill B, Kogan S. Cryptorchidism. Current concepts. *Pediatr Clin North Am*. 1997;44:1211-27.
3. Muncey W, Dutta R, Terlecki RP, Woo LL, Scarberry K. Fertility potential in adult men treated for uncorrected bilateral cryptorchidism: a systematic literature review and analysis of case reports. *Andrology*. 2021;9:781-91.
4. Gamboa Miño SN, Zeledón ME, Solari AJ, Alcántara GH. Management of an inguinal mixed Littre hernia and incidental cryptorchidism: a case report. *Int J Abdom Wall Hernia Surg*. 2022;5:200-3.
5. Singh RR, Sinha CK, Joshi A. Littre's hernia with an impalpable testis in a boy: a diagnostic dilemma. *BMJ Case Rep*. 2014;2014:bcr2014203849.

PATIENT CONSENT

Obtained.

CONFLICTS OF INTEREST

All authors report no conflict of interest.

FUNDING SOURCES


This research received no specific grant from any funding agency in the public, commercial, or not-for-profit sectors.

Rui FERREIRA-SANTOS ¹, Nuno SILVA GONÇALVES ^{1,2,3}, Cláudio BRANCO ¹, Carlos VEIGA ¹, Joaquim COSTA PEREIRA¹

1. Department of General Surgery. Unidade Local de Saúde de Braga. Braga. Portugal.

2. Life and Health Sciences Research Institute (ICVS). Universidade do Minho. Braga. Portugal.

3. Medical School. Universidade do Minho. Braga. Portugal.

 **Autor correspondente:** Rui Ferreira-Santos. ruipedro.f.santos@gmail.com

Recebido/Received: 17/02/2026 - **Aceite/Accepted:** 06/04/2026 - **Publicado/Published:** 01/06/2026

Copyright © Ordem dos Médicos 2026

<https://doi.org/10.20344/amp.24633>

