

Lung Cancer-Related Pneumopericardium

Pneumopericárdio Secundário a Cancro do Pulmão



Pedro OLIVEIRA SANTOS^{✉1}, João Pedro CALDEIRA¹
Acta Med Port 2020 34(AOP) • <https://doi.org/10.20344/amp.13802>

Keywords: Lung Neoplasms; Pneumopericardium; Tomography, Spiral Computed; X-Ray Film

Palavras-chave: Filme para Raios X; Neoplasias do Pulmão; Pneumopericárdio; Tomografia Computadorizada Espiral

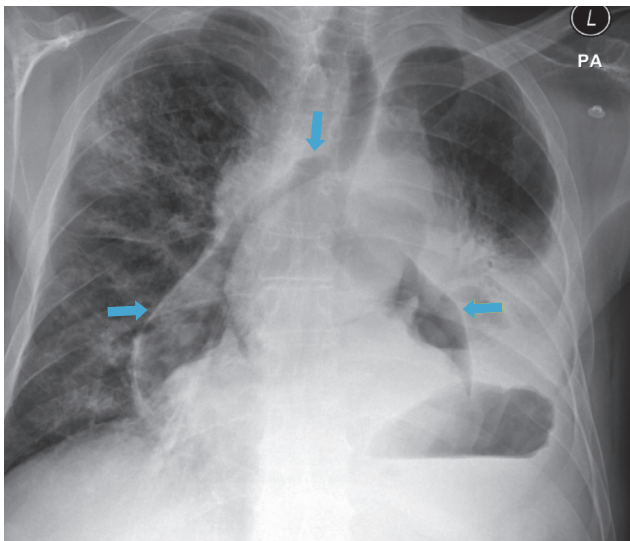


Figure 1 – Chest PA view radiograph showing air (blue arrows) around the heart, the aorta and the main pulmonary artery

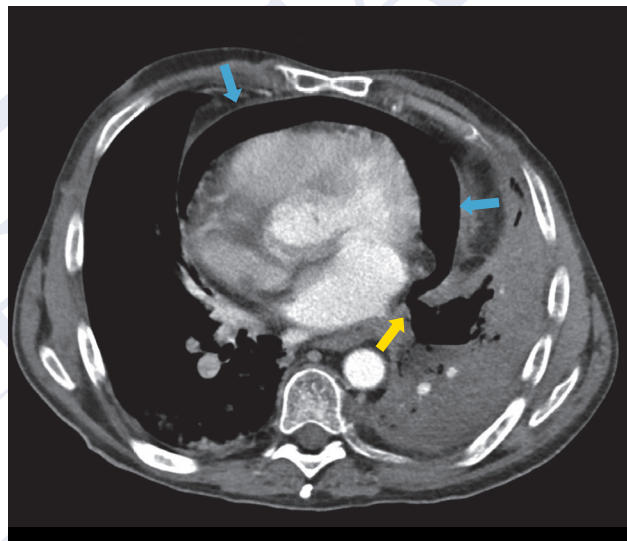


Figure 2 – Axial computed tomography image depicting the pneumopericardium (blue arrows), the broncho-pericardial fistula (yellow arrow) and the necrotic lung tumor

A 52-year-old man presented to our hospital with chest pain and shortness of breath. He was being treated with chemotherapy for a peri-hilar, infiltrative squamous cell carcinoma of the left lung with nodal involvement.

The chest radiograph (Fig. 1) revealed air outlining the inner surface of the mediastinal pleura, particularly around the aorta and the main pulmonary artery, consistent with pneumomediastinum. A computed tomography (Fig. 2) confirmed the pneumopericardium diagnosis, associated with a sizeable broncho-pericardial fistula created by the necrotic tumour.

Pneumopericardium consists of air around the mediastinal structures, often extending to the neck, chest wall or even causing pneumothorax.^{1,2} It is a rare and often fatal entity.^{3,4} Although pneumopericardium is commonly associated with blunt trauma or iatrogenic causes (such as invasive procedures or mechanical ventilation), other causes should be considered, such as cancer (particularly esophageal and lung cancer).^{1,3,4}

PROTECTION OF HUMANS AND ANIMALS: The authors declare that the procedures were followed according to the regulations established by the Clinical Research and Ethics Committee and to the Helsinki Declaration of the World Medical Association published in 2013. | **DATA CONFIDENTIALITY:** The authors declare having followed the protocols in use at their working center regarding patients' data publication. | **INFORMED CONSENT:** Obtained. | **CONFLICTS OF INTEREST:** All authors report no conflict of interest. | **FUNDING SOURCES:** The authors declare that there were no external sources of study for the performance of this article.

REFERENCES

1. Webb WR, Higgins CB. Thoracic imaging - pulmonary and cardiovascular radiology. Philadelphia: Lippincott Williams and Wilkins; 2011.
2. Bejvan SM, Godwin JD. Pneumomediastinum: old signs and new signs. Am J Roentgenol. 1996;166:1041-8.
3. Fernández Isla LE, Fernández Ruíz JS. Neumopericardio en un paciente con carcinoma de pulmón. Semergen. 2017;43:463-5.
4. Hirani S, Velez Martinez CS, Patan S, Kavanaugh M. Cancer-related pneumopericardium: a case report and literature review. Case Rep Oncol. 2020;13:23-8.

1. Serviço de Radiologia. Instituto Português de Oncologia de Lisboa Francisco Gentil. Lisboa. Portugal.

✉ Autor correspondente: Pedro Oliveira Santos. 63850@ipolisboa.min-saude.pt

Recebido: 27 de março de 2020 - Aceite: 24 de novembro de 2020 - First published: 15 de fevereiro de 2021

Copyright © Ordem dos Médicos 2021

